EYELID DISORDERS

BY: DR E. M NYENZE

DATE: 31ST/10/2016

ANATOMY :

- The eyelid is consist of four layers:
  - An anterior layer of skin and subcutaneous tissue.
  - Muscular layer that comprises the orbicularis oculi muscle, which is responsible for the closing of the lids
  - Tarsal plate which is a tough collagenous layer that houses **meibomian glands (**produce an oily substance which forms part of the tear film**)**
  - Tarsal (palpebral) conjunctiva.

- The orbital septum represents the anatomic boundary between the lid tissue and the orbital tissue.

- Innervation:
  - sensory majorly by ophthalmic and maxillary branch of trigeminal nerve.
- Blood supply
  - majorly by ophthalmic and lacrimal artery.

ANATOMY OF THE EYELIDS

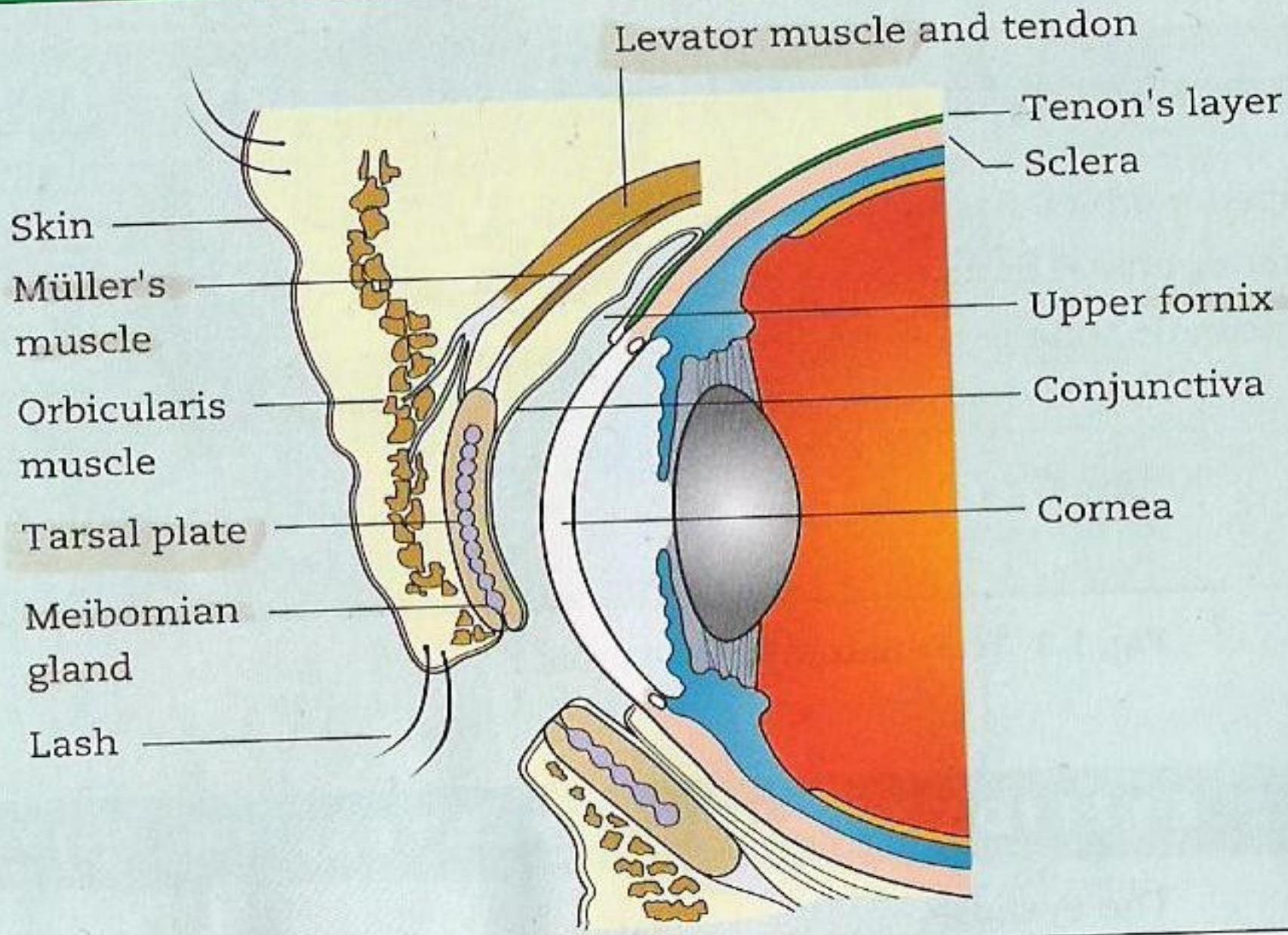

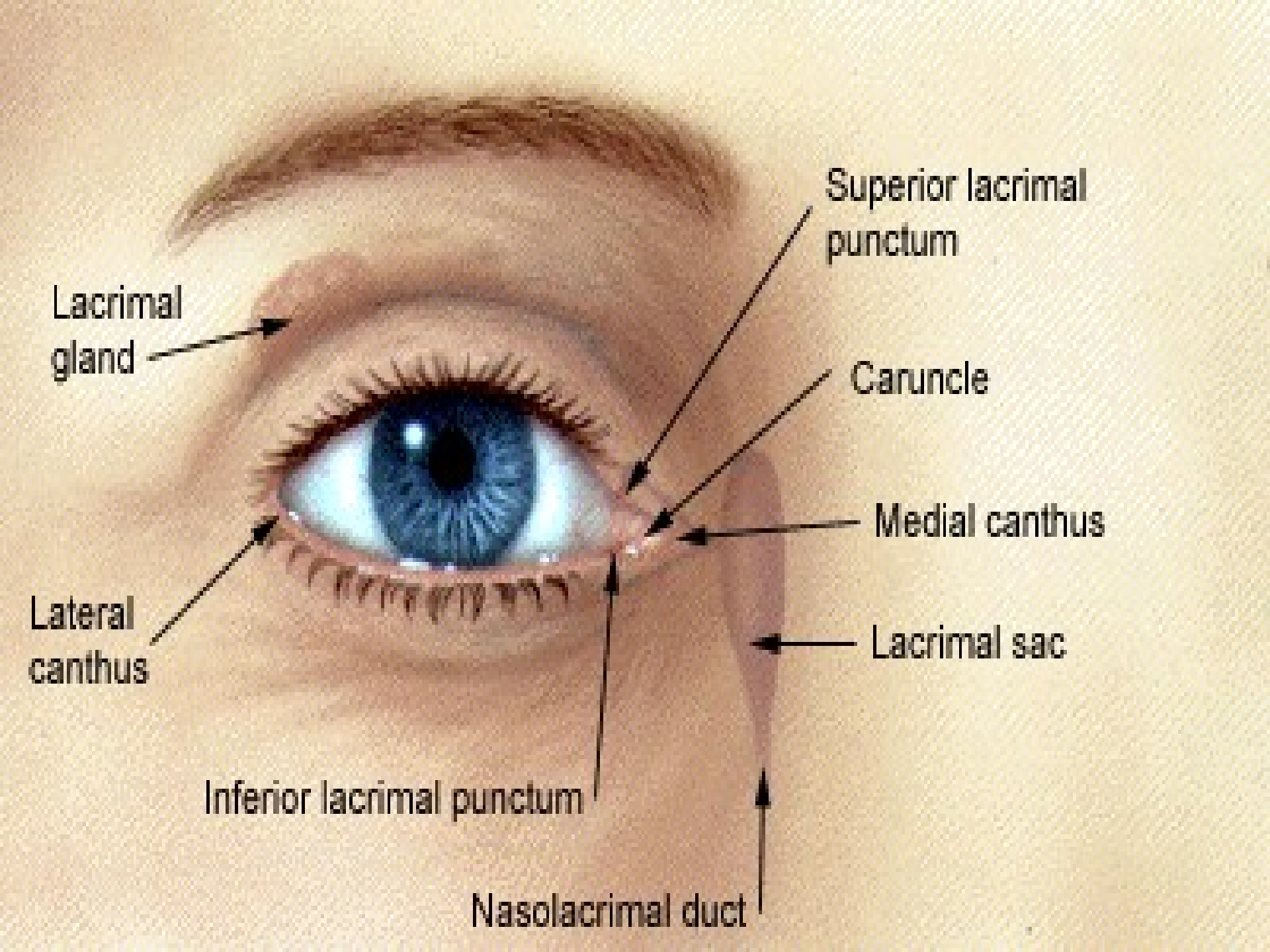
Superior lacrimal punctum
Lacrimal gland
Caruncle
Medial canthus
Lateral canthus
Lacrimal sac
Inferior lacrimal punctum
Nasolacrimal duct

FUNCTIONS OF EYELIDS

- It offers mechanical protection to anterior globe
- Spread the tear film over the conjunctiva and cornea with each blink.
- Contain the **meibomian oil glands** which provide the lipid component of the tear film.
- Prevent drying of the eyes.
- Contain the **puncta** through which the tears flow into the lacrimal drainage system.

ABNORMALITIES OF LID POSITION

- 1. PTOSIS

PTOSIS

PTOSIS

- Normally, the upper eyelid covers about a third of the cornea and the lower eyelid covers up to the limbus.
- Ptosis is an abnormally low position of the upper eyelid.
- Causes are classified as:
  - Mechanical
  - Myogenic
  - Neurogenic
  - Aponeurotic

PATHOGENESIS

It may be caused by:

1. Mechanical factors → Large lid lesions pulling down the lid.
   - Lid oedema.
   - Tethering of the lid by conjunctival scarring.
   - Dermatochalasis
   - Anterior orbital lesions

2. NEUROLOGIC FACTORS

- Third nerve palsy
- Horner's syndrome, due to a sympathetic nerve lesion
- Marcus–Gunn jaw-winking syndrome.
- Third nerve misdirection
  - History of 3rd cranial nerve palsy + regeneration in the wrong direction

CONT.

3. **Myogenic factors:**
- Myasthenia gravis
- Some forms of muscular dystrophy.
- Chronic external ophthalmoplegia
- Simple congenital
- Blepharophimosis syndrome

4. **Aponeurotic:**
- Involutional → with age
- Post-operative
- traumatic

PSEUDOPTOSIS

- Lack of support of orbital tissues e.g.
  - Enophthalmus
  - Pthisis bulbi → shrunken non-functional eyeball after severe injury
  - Micropthalmus

- Contralateral lid retraction
- Ipsilateral hypotropia → eyeball has a squint with down-gaze.
- Brow ptosis → can happen especially with age
- Dermatochalasis → the skin is excess and is overhanging.

3RD CRANIAL NERVE PALSY

Causes of isolated 3rd cranial palsy

- Idiopathic → 25%
- Vascular causes e.g. hypertension or diabetes mellitus, may present before the diagnosis;
  - Pupil sparing 3rd cranial nerve palsy may present with pain and is common with medical ptosis which is usually caused by HTN or DM.
  - Pupil involving 3rd cranial nerve palsy is caused by SDH, uncal herniation etc.; it is an emergency.
- Trauma both direct or indirect by subdural hematoma with uncal herniation
- Aneurysm of posterior communicating artery
- Miscellaneous:
  - Syphilis
  - Tumors
  - Collagen vascular disorders

MYASTHENIA GRAVIS

- Auto immune disease in which antibodies mediate damage and destruction of receptors in striated muscle
- Results in weakness and fatigability of skeletal but not cardiac or involuntary muscles
- Affects females twice as common as males
- Can be:
  - Ocular → ocular muscles
  - Bulbar → Nasopharyngeal muscles
  - Generalized → other skeletal muscles in the body
- Presents mainly from third decade, but may present from any age from first year of life
- Commonly presents with **diplopia and ptosis**
- Generalized involvement usually presents with painless fatigue
- Ocular involvement occurs in 90% of cases and is the presenting feature in 60%
- MG extra-ocular motility
  - Migratory
  - Can involve any extra-ocular muscle in any pattern unlike 3rd nerve palsy

CONT.

- Ptosis
  - Insidous, bilateral and usually asymmetrical
  - Worse at end of the day

- Edrophonium/Tensilon test
  - Injection of a short acting anticholinesterase
  - Increases amount of acetylcholine at NMJ
  - Results in transient improvement of symptoms

TREATMENT OPTIONS

- Anticholinesterase drugs
  - Pyridostigmine
  - Neostigmine
- Steroids
- Immunosuppressants
  - Azathioprime
  - Cyclosporine
- Plasma exchange
- Intravenous immunoglobulins
- Do CXR to look for thymoma and if present perform thymectomy
  - This is not useful for pure ocular MG

HORNERS SYNDROME

- Muller muscle is a smooth muscle that assists in elevation of the eye lid. It is innervated by the sympathetic chain.

- **Central causes**
  - Brainstem disease
  - Syringomyelia
  - Lateral medullary syndrome
  - Spinal cord tumors

- **Preganglionic causes**
  - Pancoast tumor
  - Carotid and aortic aneurysms and dissection
  - Neck lesions

POST-GANGLIONIC CAUSES (TRAVEL WITH BLOOD VESSELS)

- Cluster headaches/ migraneus neuralgia
- Internal carotid artery dissection
- Nasopharyngeal tumors
- Otitis media
- Cavernous Sinus mass

CLINICAL FEATURES

- Mild ptosis 1-2 mm due to weakness of Mulers muscle
- Slight elevation of lower lid due to weakness of inferior tarsal muscle.
- Miosis and anisocoria accentuated by dim light
- Normal reaction to light and near
- Reduced ipsilateral sweating but only if the lesion is below the superior ganglion

MARCUS GUNN JAW–WINKING SYNDROME/TRIGEMINO–OCULOMOTOR SYNKINESIS

- Autosomal dominant condition
- In this congenital ptosis there is mis-wiring of the nerve supply to the pterygoid muscle of the jaw and the levator of the eye so that the eyelid moves in conjugation with movements of the jaw.

Treatment

- Treatment is usually unnecessary but in severe cases, surgery with a bilateral levator excision and frontalis brow suspension may be used.

SIMPLE CONGENITAL PTOSIS

- Usually caused by failure of neuronal migration or development.
- Presents with
  - Unilateral or bilateral ptosis in childhood
  - Absent upper lid crease
  - poor levator function
  - in down gaze, the ptotic lid is higher than the normal (lid lag)
  - Can be associated with SR weakness
  - can have compensatory chin elevation

- Treated by:
  - Levator resection or;
  - Tarsofrontalis sling

INVOLUTIONAL PTOSIS

- An age-related condition caused by dehiscence, dis-insertion or stretching of levator aponeurosis
- Usually presents with ptosis with a high upper lid crease
- Levator function usually good
- Should not be confused with MG because ptosis gets worse during the day
- Levator function usually good
- Levator resection and reinsertion done

THIRD NERVE MISDIRECTION SYNDROMES

- May be congenital or more commonly follows acquired third nerve palsies
- Presents with bizzare movements of the upper lid which accompany various eye movements
- Treated by levatore disinsertion and brow suspension

ENTROPION

- It is an in-turning, usually of the lower lid towards the globe.
- Patients present with irritation caused by eyelashes rubbing on the cornea.
- More common in elderly, because orbicularis muscle become spasm.
- It may also caused by conjunctival scarring distorting the lid (cicatrical entropion)
- Treatment:
  - Short term:
    - include the application of lubricants to the eye or taping of the eyelid.
  - Permanent:
    - surgery

ECTROPION

- Eversion of the lid away from the globe.
- **Causes:-**
  - age related orbicularis muscle laxity.
  - facial nerve palsy.
  - scarring of periorbital skin.
- Initial complaint of watery eye, because the mal-position of the lids everts the puncta and prevents drainage of the tears leading to epiphora (overflow of the tears over the cheeks)
- It also exposes the conjunctiva leading to irritable eye.
- Treatment: surgical

LID INFLAMMATION

HERPES ZOSTER OPHTHALMICA

- Caused by varicellla zoster virus
- Typically occurs in elderly patients but can occur earlier commonly in immunosupressed patients
- Starts with pain in distribution of first division of trigeminal nerve
- Maculopapular rash-vesicles-pustules-crusting
- Periorbital oedema

DermNetNZ.org

ACUTE EYE DISEASE IN HZO

- Acute epithelial keratitis
- Conjunctivitis
- Episcleritits
- Scleritis
- Uveitis
- Chronic disease
  - Lid scaring
  - Post herpetic neuralgia

TREATMENT OPTIONS

- Oral acyclovir
- IV acyclovir indicated for encephalitis
- Oral valaciclovir, famciclovir
- Systemic steroids (in combination with antivirals)
- Acyclovir ointment and bacitracin ointment

LID LUMPS

CHALAZION

- It is a granuloma within the tarsal plate caused by obstructed meibomian gland.
- Painless.
- Symptoms are unsightly:
  - Lid swelling which resolve within six months if the lesion persist we remove it surgically

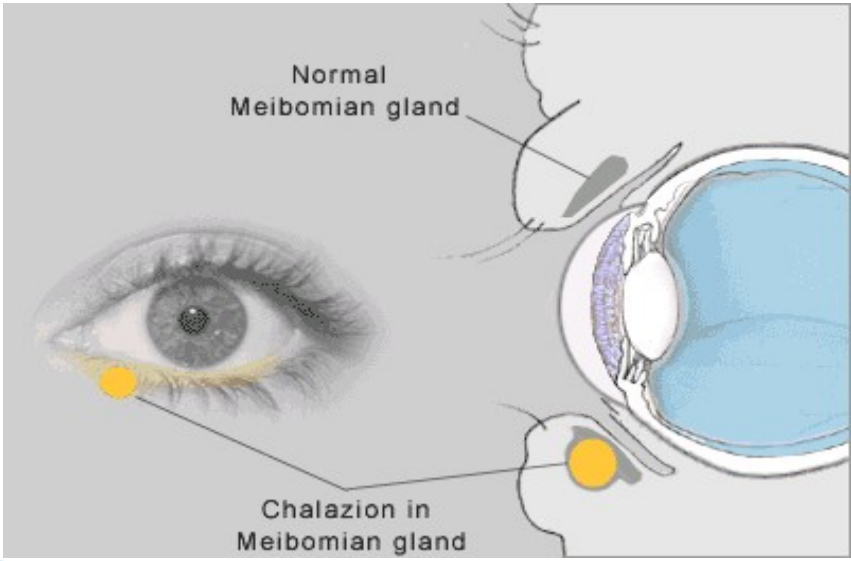

INTERNAL HORDEOLUM

- An abscess in meibomian gland.
- Painful.
- May respond to topical antibiotics but incision by be necessary.

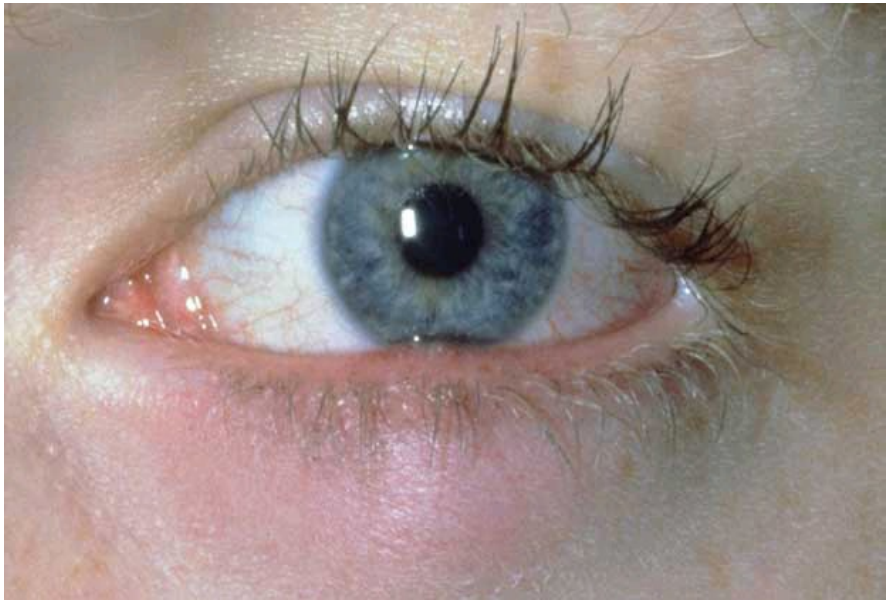

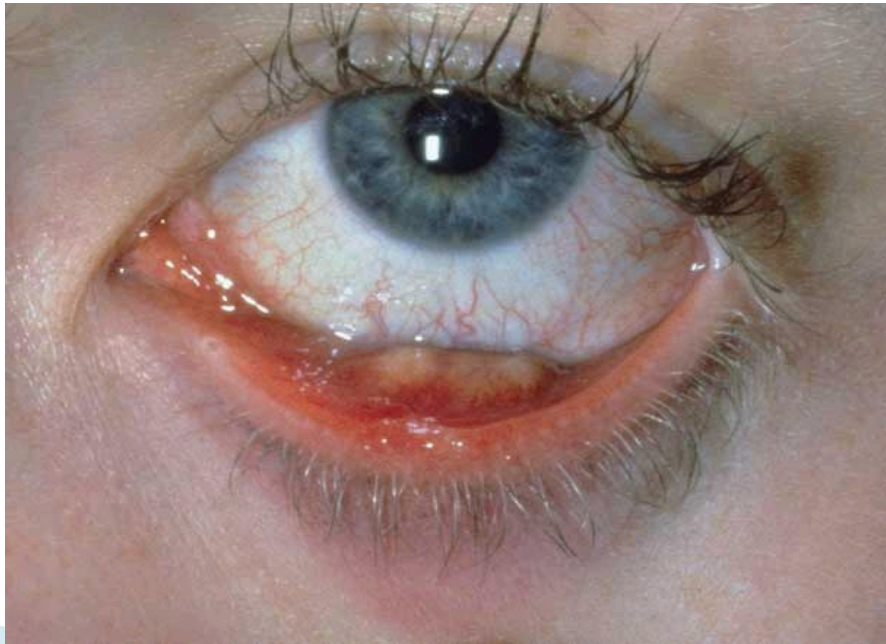

EXTERNAL HORDEOLUM (STYE)

- It is an abscess in eyelash follicle.
- Painful.
- Most cases are self limiting.
- Treatment requires the removal of the associated eyelash and application of hot compresses.

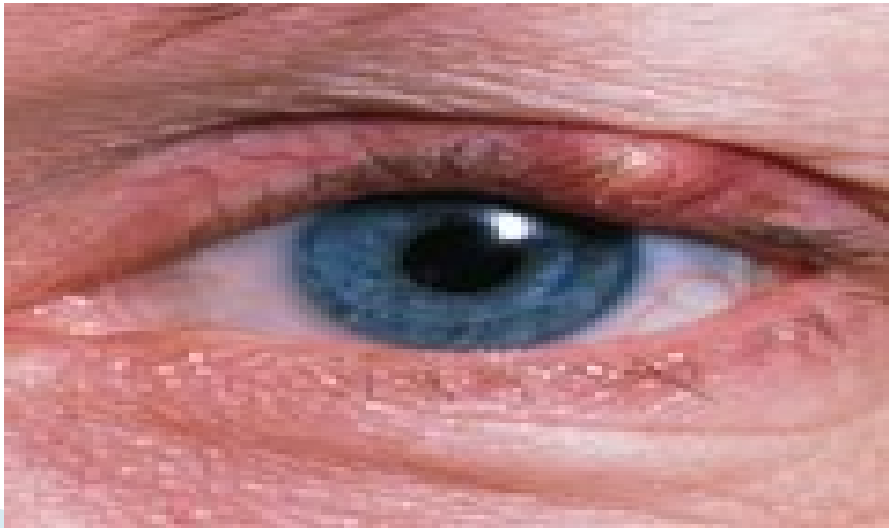

MOLLUSCUM CONTAGIOSUM

- Is a viral infection of the skin or the mucous membranes, caused by pox virus.
- Can be presented with umbilicated lesion found on the lid margin.
- Cause irritation, redness, follicular conjunctivitis (small elevation of lymphoid tissue found on tarsal conjunctiva)
- Treatment requires excision of the lid lesion.

XANTHELASMA

- Lipid containing bilateral lesions.
- Usually associated with hyperlipidemia .
- Removed for cosmetic reasons.

FACIAL DYSTONIA

- Hemi-facial spasm
- Intermittent, synchronous gross contractures of the entire side of the face, rarely bilateral.
- Symptoms present during sleep
- Usually associated with ipsilateral facial nerve weakness
- Usually caused by vascular compression of facial nerve at brainstem - can be seen with MRI (To rule out pontine gliomas)
- Treatment options
  - Botulin toxin injections
  - Neurosurgical decompression

BENIGN ESSENTIAL BLEPHAROSPASM

- Usually bilateral
- Presents with increased blinking and involuntary spasms of orbicularis, procerus and corrugator muscles
- May present with episodic inability to open both eyes
- Age above 40 years
- Cause unknown, severe dry eyes may present simillary
- Diagnosis clinical
- Treatment botulin toxin and surgical myomectomy of orbicularis

THANK YOU